

## Therapeutic Effects of Cellular Therapy in a Case of Adult Autism Spectrum of Disorder

Alok Sharma<sup>1</sup>, Nandini Gokulchandran<sup>1</sup>, Hemangi Sane<sup>1</sup>, Pooja Kulkarni, Samson Nivins<sup>2\*</sup>, Maitree Maheshwari<sup>3</sup>, Prerna Badhe<sup>4</sup>

1. Department of Medical Services and Clinical Research, NeuroGen Brain & Spine Institute, Navi Mumbai, India.
2. Department of Research & Development, NeuroGen Brain & Spine Institute, Navi Mumbai, India.
3. Department of Psychology, NeuroGen Brain & Spine Institute, Navi Mumbai, India.
4. Department of Regenerative laboratory services, NeuroGen Brain & Spine Institute, Navi Mumbai, India.

Submitted 8 Mar 2018; Accepted 4 Apr 2018; Published 11 May 2018

Adults with autism spectrum disorder (ASD) experience significant impairments in social interaction, poor planning, decision making, timing and motor skills which impact on their daily activities of living and ability to access the health care services. Early research on ASD primarily focused on children with service provision for adults is still in its infancy. The current treatment for adults with ASD is complex, considering the diverse etiology and characteristics. In this study, a 25-year-old male diagnosed with ASD at the age of 7 years underwent intrathecal autologous bone marrow derived mononuclear cells (BMMNCs) administration, followed by neurorehabilitation. Following six months of cell therapy, the patient showed improvement in concentration, attention, command following, sitting tolerance, social interactions, eye contact, and memory. His Childhood Autism Rating Scale (CARS), Indian Scale of Assessment of Autism (ISAA), Functional Independence Measure (FIM) scores improved from 36 to 34, 87 to 78, and 65 to 78, respectively. As compared to pre-intervention, brain <sup>18</sup>F-FDG PET/CT scan showed improvement in supramarginal gyrus, thalamus, basal ganglia, medial temporal cortex and cerebellum. This study suggests the efficacy of autologous BMMNCs in addressing the core neurodeficits of adult ASD, and thereby improving the quality of life.

**Keywords:** Adult, autism spectrum disorder, stem cell therapy, autologous, bone marrow derived mononuclear cells, stem cells, PET/CT scan

Autism Spectrum Disorders (ASD) refers to a group of neurodevelopmental conditions characterized by deficits in social interaction and communication, hyperactivity, stereotyped repetitive behavior and restricted interests (1). Cognitive, emotional, and neurobehavioral abnormalities represent the core symptoms (1). Genetic, environmental and epigenetic factors play

an important role in increased incidence of ASD. The other risk factors include familial history, maternal age, paternal age, birth weight, prematurity, and presence of birth defects (2). Previous research studies on ASD have primarily focused on children. However, it is a life long neurodevelopmental disorder with symptoms continuing in the adulthood.

Despite of remarkable progress towards understanding the pathophysiology of ASD, there is no definite cure available for the disorder. Health and education services are well established for children, however there is lack of service provision for adults (3). Adults with ASD have significantly increased rate of mental health problems including depression, anxiety, bipolar affective disorder, obsessive compulsive disorder, psychosis, and self harm (4-6). Moreover, these comorbid mental health difficulties prevail from childhood to adulthood (7). Furthermore, adult ASD have specific cognitive anomalies including poor planning, decision making, timing and motor skills which impact on their daily activities of living and ability to access the health care services (8-9).

Different treatments like pharmacological therapies, occupational therapy, speech and language therapy, behavioural and developmental approaches have been proposed to improve the symptoms associated with adult ASD (10). But the core underlying damage to the brain remains unaddressed. Cell therapy has emerged as a promising tool to repair and regenerate damaged tissues through its neuroprotective and neuroregenerative properties (11). These cells possess characteristics which include self renewal, differentiation process, and paracrine effects making them viable for therapeutic and clinical application in adult ASD. In this study, we administered autologous bone marrow derived mononuclear cells intrathecally in an adult ASD patient to study the effectiveness of cell therapy. <sup>18</sup>F-FDG PET/CT imaging was used to monitor the changes occurring at the cellular level.

### Materials and methods

A 25 year-old male, diagnosed with ASD was studied. Maternal age was 37 years at conception, and mother had high blood pressure throughout pregnancy. He was born of caesarean section delivery at full term with normal weight, cried immediately after birth, and had no history of

neonatal illness. All his motor milestones were achieved at appropriate age, and schooling started at 3 years. First episode of seizure was at the age of 3 years in the form of shivering and rolling up of the eyes. Following seizures, there was deterioration in speech and overall development with poor eye contact, hyperactivity and repetitive behavior. The frequency of seizures was uncertain, and he was prescribed on antiepileptics. He discontinued schooling at 3 ½ years of age because of his speech and behavioural complaints. At the age of 7 years, based on his symptomatic clinical features, he was diagnosed as ASD by a neurologist. He was under medications for seizures till 14 years of age. He started special schooling again at the age of 23 years.

On our assessment at age of 25 years, he showed poor social interaction, fleeting eye contact, attention and concentration deficit. He also showed poor cognition, poor problem solving skills, poor awareness, poor attention and judgment skills with impairment in answering age appropriate questions. There was presence of stereotypical behavior, laughing without any reason, and irrelevant motor mannerism. He could not indicate pain and convey his needs to others. Functionally, he was dependent for all his activities of daily living. On Indian Scale for Assessment of Autism (ISAA), he scored 87 and on Childhood Autism Rating Scale (CARS), he scored 36 suggestive of moderate autism, and on functional independence measure (FIM), he scored 65.

2-deoxy-2-[fluorine-18]fluoro- D-glucose integrated with computed tomography (<sup>18</sup>F-FDG PET/CT) showed hypometabolism in the supramarginal gyrus, thalamus, basal ganglia, medial temporal cortex and cerebellum. Magnetic resonance imaging (MRI) brain visual analysis of the 3D T1, T2 weighted sequence showed no significant abnormality in the brain parenchyma. Diffused tensor imaging (DTI) fibertracking showed symmetry and normal cortico-pyramidal tracts. The fractional anisotropy (FA) values in the brain parenchyma were within the normal limits.

The Electroencephalogram (EEG) was normal in the sleep state with no potentially epileptiform activity present.

#### Patient recruitment and cell therapy procedure

Patient selection was based on World Medical Associations Helsinki declaration (12). The complete protocol was reviewed and approved by the Institutional Committee for Stem-cell Research and Therapy (IC-SCRT). The procedure of the intervention was explained in detail to the parents, and a duly filled informed consent was obtained prior to the therapy. Before cell therapy, the patient underwent a complete evaluation consisting of neurological, psychological examination along with routine biochemical and serological tests.

The patient was administered with granulocyte colony stimulating factor (G-CSF) (300 mcg) subcutaneously, 72 h and 24 h prior to the procedure of cell therapy. On the day of transplantation, approximately 120 ml of bone marrow was aspirated from the right anterior superior iliac spine using aspiration needle, and was collected in heparinized tubes. Mononuclear cells (MNCs) were obtained by density gradient separation. The isolated MNCs were checked for viability using trypan blue dye, which was found to be 96%. The MNCs were checked for CD34<sup>+</sup> by fluorescence activated cell sorting (FACS) using CD34 PE antibody, which was found to be 6.30%. Approximately  $1.45 \times 10^8$  MNCs were immediately injected after separation, intrathecally in lumbar region (L4-L5) using a lumbar puncture needle. Simultaneously, intravenous methylprednisolone 1 g in 500 ml Ringer Lactate was administered during the procedure of cell transplantation to avoid immediate local reaction to the injected cells, and enhance their survival.

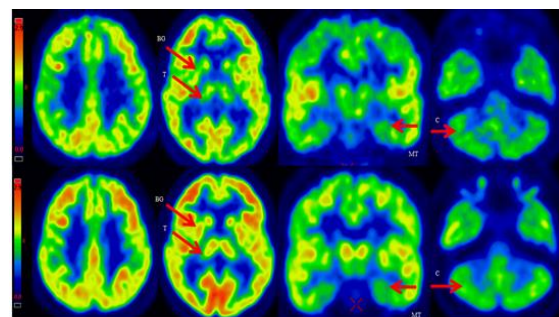
Following cell therapy, he underwent personalised neurorehabilitative regime which included psychological intervention, special education occupational therapy, and physiotherapy.

These therapies aimed at effective motor learning Strategies with task oriented training. Psychological intervention aimed at improving concept and tolerance level in the patient.

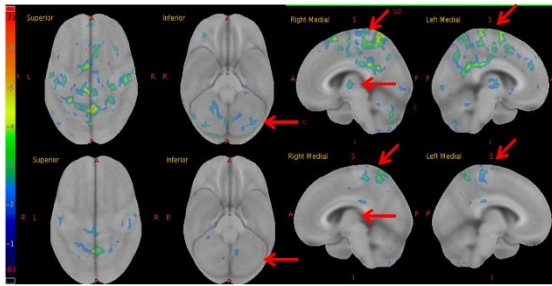
#### Results

The patient was followed up after six months of cell therapy. No major adverse events were recorded. He showed improvements in concentration, sitting tolerance, social interactions, and memory. Awareness regarding the surroundings improved with better utilisation of the objects. Attention while having a conversation had improved with a proper eye contact. Basic command following had improved. Hyperactivity had reduced significantly. He also developed efficiency in carrying out his ADLs such as bathing independently, and maintaining toilet hygiene. Sleep pattern was comparatively better. He also started to get involved in extra curricular activities like painting. His CARS, ISAA and FIM scores improved from 36 to 34, 87 to 78 and 65 to 78, respectively.

<sup>18</sup>F-FDG PET/CT scan performed six months after the cell therapy showed significant improvement in supramarginal gyrus, thalamus, basal ganglia and mild improvement in medial temporal cortex and cerebellum (Fig. 1, 2).



**Figure 1.** <sup>18</sup>F-FDG PET/CT scan illustrating the effect of cell therapy in ASD. Top row: focal regions of interest (ROI) of hypometabolism that is well defined before cell therapy; Bottom row: areas of improved metabolism in <sup>18</sup>F-FDG PET/CT images, six months after interventions of cell therapy. ROI included are Medial parietal cortex (MP), Thalamus (T), Basal ganglia (BG), Medial temporal cortex (MT), and Cerebellum (C).



**Figure 2.** Z score images of a patient with ASD before and following cell therapy. Images were presented in axial and coronal. (Top) row: A significant decrease in distribution of  $^{18}\text{F}$ -FDG is indicated by arrow before cell therapy; (Bottom) row: six months after the intervention of cell therapy shows improvement in the region of hypometabolism. Regions of interest (ROI) included are Medial parietal cortex (MP), Thalamus (T), and Cerebellum (C).

## Discussion

Adults with ASD often suffer from social isolation, depression and anxiety disorders as compared to other developmental disorders (13). Additionally, most individuals with adult ASD remain dependent on their families or caretakers. The traditional treatment modalities aim at alleviating the symptomatic representation in ASD, and providing the patient with a better quality of life. Cell therapy has emerged as a potential treatment for adult ASD as it addresses the core neuropathology of the brain through its immunomodulatory and neurorestorative properties (14). The immune and neural dysfunctions, inflammation, excitatory and inhibitory imbalance and impaired GABAergic system in adult ASD provides a specific target for cell therapies.

To study its effect in adult ASD, we administered the patient with autologous bone marrow mononuclear cells (BMMNCs) intrathecally. BMMNCs are a heterogeneous mixture of cells that include endothelial progenitor cells, hematopoietic stem cells, mesenchymal stem cells, and multipotent adult progenitor cells (15). They offer an advantage of imparting a combined effect of all the different cell types (16-18). Multitude of clinical studies with different types of cells have shown improved behaviour, attention and concentration, emotional reciprocity, eye contact, reduced hyperactivity and aggressiveness, thereby

proving the efficacy of cell therapy in ASD. These improvements were supported by improved scores of the objective scales and PET/CT imaging studies (19-22). Intrathecal administration of BMMNCs allows the cells to migrate into the target region of the brain through the cerebrospinal fluid (23-24). Autologous cells are safe and feasible as they are available in adequate quantity, and devoid of the risk of immune rejection.

Studies have suggested alteration in the blood brain barrier (BBB) in autism due to neuroinflammation resulting from increase in inflammatory cytokines, immune dysregulation, and activation of neuroglial cells in the brain (25-26). The altered permeability of BBB allows the BMMNCs, when injected intrathecally, to effectively reach the brain regions with marked inflammation, and counteract these pathologies through its immunomodulatory properties (27-29). It causes an increase in the anti-inflammatory molecules like TGF- $\beta$  and IL-10, and suppression of pro-inflammatory cytokine like TNF- $\alpha$ , IL-1 $\beta$  and INF- $\gamma$  (27, 30). These cells promote neovascularisation, and exert paracrine secretion of neurotrophic factors like fibroblast growth factor (FGF2), vascular endothelial growth factor (VEGF), and ciliary neurotrophic factor (CNTF) (31-32). This facilitates angiogenesis, and stimulates the repair by enhancing proliferation, cell recruitment, and maturation of endogenous stem or progenitor cells (33). All these mechanisms improve the brain metabolism, synaptogenesis and perfusion, restoring the neuronal function and integrity. Hence, we propose that combined mechanism of cell therapy may help in counterbalancing the immune system aberration, and simultaneously activating endogenous restorative mechanism within targeted tissues, contributing to neuronal and functional recovery in patients with adult ASD.

In this study, we used  $^{18}\text{F}$ -FDG PET/CT imaging as a monitoring tool for establishing the effect of cell therapy.  $^{18}\text{F}$ -FDG PET/CT scan has been widely used in routine clinical work for studying the synaptic activity, neuronal function,

and neuronal metabolic activity of the brain (34). Comparative <sup>18</sup>F-FDG PET/CT, performed after six months of cell therapy, suggested a significant improvement in glucose metabolism as witnessed by clinical improvements shown in Table 1.

The intervention also involved multi-disciplinary rehabilitation regime. Exercise induces mobilization of local stem cells, enhances neuronal proliferation and reorganization of neural network by improving blood flow and release of neurotrophic factors (35). Cell therapy combined with rehabilitation enhances the outcome of intervention leading to functional and clinical improvements. Cell therapy can be used in combination with the conventional treatments to augment the outcome.

The present study is a singular case to establish the therapeutic effects of cell therapy in adult ASD. However, the patient was undergoing rehabilitation before the intervention without any significant improvement. Hence, the functional and clinical improvements occurring after the intervention can be significantly attributed to cellular therapy.

In conclusion, autologous BMMNC transplantation in combination with neurorehabilitation not only addresses the pathophysiology of ASD but also leads to functional and symptomatic improvements. It is a safe, feasible and effective treatment modality. The combined mechanism of cell therapy along with neurorehabilitation can make the adult individual with ASD functionally independent, and allow their amalgamation into the outside world thereby improving their quality of life.

Further studies of cell therapy for adult ASD should be conducted.

**Table 1.** Regional correlation between associated brain region and clinical improvements

Brain regions	Clinical improvements
Cerebellum and basal ganglia	Eye contact, sitting tolerance, awareness, and behavior
Medial temporal cortex	Social interactions and memory

### Conflict of interest

The authors declare that they have no competing interest.

### References

1. Siniscalco D. Current Findings and Research Prospective in Autism Spectrum Disorders. *Autism S2: e001*. 2013;10:2165-7890.
2. Investigators D D M N S Y P and Centers for Disease C a P. Prevalence of autism spectrum disorder among children aged 8 years -autism and developmental disabilities monitoring network, 11 sites, United States, 2010. *MMWR Surveill Summ*. 2014;63:1-21.
3. Murphy C M, Wilson C E, Robertson D M, et al. Autism spectrum disorder in adults: diagnosis, management, and health services development. *Neuropsychiatr Dis Treat*. 2016;12:1669-86.
4. Hofvander B, Delorme R, Chaste P, et al. Psychiatric and psychosocial problems in adults with normal-intelligence autism spectrum disorders. *BMC Psychiatry*. 2009;9:35.
5. Lugnegard T, Hallerback M U, Gillberg C. Psychiatric comorbidity in young adults with a clinical diagnosis of Asperger syndrome. *Res Dev Disabil*. 2011;32:1910-7.
6. Russell a J, Mataix-Cols D, Anson M, et al. Obsessions and compulsions in Aspergersyndrome and high-functioning autism. *Br J Psychiatry*. 2005;186:525-8.
7. Simonoff E, Jones C R, Baird G, et al. The persistence and stability of psychiatric problems in adolescents with autism spectrum disorders. *J Child Psychol Psychiatry*. 2013;54:186-94.
8. Green J, Gilchrist A, Burton D, et al. Social and psychiatric functioning in adolescents with Asperger syndrome compared with conduct disorder. *J Autism Dev Disord*. 2000;30:279-93.
9. Wilson C E, Happe F, Wheelwright S J, et al. The neuropsychology of male adults with high-functioning autism or asperger syndrome. *Autism Res*. 2014;7:568-81.
10. Cohen D J and Volkmar F R, *Handbook of autism and pervasive developmental disorders*. John Wiley & Sons Inc. 1997.
11. Chen Q, Long Y, Yuan X, et al. Protective effects of bone marrow stromal cell transplantation in injured rodent brain: synthesis of neurotrophic factors. *J Neurosci Res*. 2005;80:611-9.
12. General Assembly of the World Medical A. World Medical



Association Declaration of Helsinki: ethical principles for medical research involving human subjects. *J Am Coll Dent.* 2014;81:14-8.

13. Bradley E A, Summers J A, Wood H L, et al. Comparing rates of psychiatric and behavior disorders in adolescents and young adults with severe intellectual disability with and without autism. *J Autism Dev Disord.* 2004;34:151-61.

14. Siniscalco D, Sapone A, Cirillo A, et al. Autism Spectrum Disorders: Is Mesenchymal Stem Cell Personalized Therapy the Future? *J Biomed Biotechnol.* 2012;2012:1-6.

15. Seeger F H, Rasper T, Koyanagi M, et al. CXCR4 expression determines functional activity of bone marrow-derived mononuclear cells for therapeutic neovascularization in acute ischemia. *Arterioscler Thromb Vasc Biol.* 2009;29:1802-9.

16. Li W Y, Choi Y J, Lee P H, et al. Mesenchymal stem cells for ischemic stroke: changes in effects after ex vivo culturing. *Cell Transplant.* 2008;17:1045-59.

17. Liu Z, Li Y, Zhang R L, et al. Bone marrow stromal cells promote skilled motor recovery and enhance contralesional axonal connections after ischemic stroke in adult mice. *Stroke.* 2011;42:740-4.

18. Song M, Mohamad O, Gu X, et al. Restoration of intracortical and thalamocortical circuits after transplantation of bone marrow mesenchymal stem cells into the ischemic brain of mice. *Cell Transplant.* 2013;22:2001-15.

19. Lv Y T, Zhang Y, Liu M, et al. Transplantation of human cord blood mononuclear cells and umbilical cord-derived mesenchymal stem cells in autism. *J Transl Med.* 2013;11:196.

20. Sharma A, Gokulchandran N, Sane H, et al. Autologous Bone Marrow Mononuclear Cell Therapy for Autism: An Open Label Proof of Concept Study. *Stem Cells International.* 2013;2013:1-13.

21. Sharma A, Gokulchandran N, Sane H, et al. Intrathecal Autologous Bone Marrow Mononuclear Cell Transplantation in a Case of Adult Autism. *Autism.* 2013;3:113.

22. Sharma A, Gokulchandran N, Shetty A, et al. Autologous Bone Marrow Mononuclear Cells may be Explored as a Novel Potential Therapeutic Option for Autism. *Clinical Case Reports.* 2013;3.

23. Callera F and De Melo C M. Magnetic resonance tracking of magnetically labeled autologous bone marrow CD34+ cells transplanted into the spinal cord via lumbar puncture technique in

patients with chronic spinal cord injury: CD34+ cells' migration into the injured site. *Stem Cells Dev.* 2007;16:461-6.

24. Callera F and Do Nascimento R X. Delivery of autologous bone marrow precursor cells into the spinal cord via lumbar puncture technique in patients with spinal cord injury: a preliminary safety study. *Exp Hematol.* 2006;34:130-1.

25. Avison M J, Nath A, Greene-Avison R, et al. Inflammatory changes and breakdown of microvascular integrity in early human immunodeficiency virus dementia. *J Neurovirol.* 2004;10:223-32.

26. Amor S, Puentes F, Baker D, et al. Inflammation in neurodegenerative diseases. *Immunology.* 2010;129:154-69.

27. Aggarwal S and Pittenger M F. Human mesenchymal stem cells modulate allogeneic immune cell responses. *Blood.* 2005;105:1815-22.

28. Raffaghello L, Bianchi G, Bertolotto M, et al. Human mesenchymal stem cells inhibit neutrophil apoptosis: a model for neutrophil preservation in the bone marrow niche. *Stem Cells.* 2008;26:151-62.

29. English K. Mechanisms of mesenchymal stromal cell immunomodulation. *Immunol Cell Biol.* 2013;91:19-26.

30. Beyth S, Borovsky Z, Mevorach D, et al. Human mesenchymal stem cells alter antigen-presenting cell maturation and induce T-cell unresponsiveness. *Blood.* 2005;105:2214-9.

31. Deregibus M C, Cantaluppi V, Calogero R, et al. Endothelial progenitor cell derived microvesicles activate an angiogenic program in endothelial cells by a horizontal transfer of mRNA. *Blood.* 2007;110:2440-8.

32. Kinnaird T, Stabile E, Burnett M S, et al. Local delivery of marrow-derived stromal cells augments collateral perfusion through paracrine mechanisms. *Circulation.* 2004;109:1543-9.

33. Nakano-Doi A, Nakagomi T, Fujikawa M, et al. Bone marrow mononuclear cells promote proliferation of endogenous neural stem cells through vascular niches after cerebral infarction. *Stem Cells.* 2010;28:1292-302.

34. Sokoloff L. Relationships among local functional activity, energy metabolism, and blood flow in the central nervous system. *Fed Proc.* 1981;40:2311-6.

35. Kirk-Sanchez N J and Mcgough E L. Physical exercise and cognitive performance in the elderly: current perspectives. *Clin Interv Aging.* 2014;9:51-62.