

# Autologous Bone Marrow Mononuclear Cell Transplantation with Neurorehabilitation for Cerebral Palsy

Alok Sharma<sup>1,2</sup>, Hemangi Sane<sup>2</sup>, Sarita Kalburgi<sup>2,3</sup>, Pooja Kulkarni<sup>2\*</sup>, Khushboo Bhagwanani<sup>3</sup>, Nandini Gokulchandran<sup>1</sup>, and Prerna Badhe<sup>4</sup>

<sup>1</sup>Department of Regenerative Medicine and Medical Services, NeuroGen Brain and Spine Institute, India

<sup>2</sup>Department of Research & Development, NeuroGen Brain and Spine Institute, India

<sup>3</sup>Department of Neuro Rehabilitation, NeuroGen Brain and Spine Institute, India

<sup>4</sup>Department of Regenerative Laboratory Services, NeuroGen Brain and Spine Institute, India

**Received Date:** November 17, 2016, **Accepted Date:** February 13, 2017, **Published Date:** February 23, 2017.

\***Corresponding authors:** Pooja Kulkarni, NeuroGen Brain and Spine Institute, StemAsia Hospital & Research Centre, Sector 40, Plot No 19, Palm Beach Road, Seawoods (W), New Mumbai, Maharashtra, India, 400706, E-mail: [publications@neurogen.in](mailto:publications@neurogen.in)

## Abstract

Cerebral palsy (CP) is characterized by a non-progressive motor impairment related to brain injury early in development. It may be associated with other deficits such as intellectual disability, speech and language and oromotor problems. In many cases, the cause of CP may not be apparent. So, the current treatment options are mostly focused on the symptomatic management. Herein, we present a case of an eight year old child diagnosed as cerebral palsy with intellectual disability. He was administered with autologous bone marrow derived mononuclear cells intrathecally. Eight months after intervention, Gross Motor Function Measure (GMFM) scale score changed from 1.9 to 3.077 depicting improvement in movement. On follow up improvements were noticed in oromotor functions, neck control and sitting balance, awareness, understanding of surrounding. These functional improvements correlated with the improved brain metabolism in basal ganglia, cerebellum, hippocampus and thalamus as observed in Positron Emission Tomography-Computed Tomography (PET-CT) Scan. No major side effects were recorded after intervention. The results suggest that autologous bone marrow derived mononuclear cells have a significant potential as a therapeutic strategy for CP.

**Keywords:** Cerebral Palsy; Cellular Therapy; Autologous; Bone Marrow Derived Mononuclear Cells; Positron Emission Tomography-Computed Tomography Scan

## Abbreviations

CP: Cerebral palsy; GMFM: Gross Motor Function Measure; PET-CT: Positron Emission Tomography –Computed Tomography; CDC: Centers of Disease Control; BMMNCs: Bone Marrow Derived Mononuclear Cells; NICU: Neonatal Intensive Care Unit; MRI: Magnetic Resonance Imaging; WeeFIM: Functional Independence Measure; GMFCS: Gross Motor Function Classification System; EEG: Electroencephalogram; IC-SCRT: Stem Cell Research and Therapy; G-CSF: Granulocyte Colony-Stimulating Factor; NDT: Neurodevelopmental Therapy; SD: Standard Deviation; FDG: Flurodeoxyglucose; PVL: Periventricular leukomalacia; GMFM: Gross Motor Function Measure; SUV: Standardized Uptake Values.

## Introduction

Cerebral Palsy (CP) is a group of permanent neurological disorders affecting movement, posture, muscle co-ordination and balance [1]. These motor disorders are also accompanied by affected cognition, perception, sensation, communication and behavior [1]. Intellectual disability coexists in 30% of the cases with CP [2]. They have some common etiological factors, which limit functions and affect quality of life of these patients [3]. According to the Centers of Disease Control (CDC), worldwide prevalence of CP ranges from 1.5 to 4 per 1,000 live births [4].

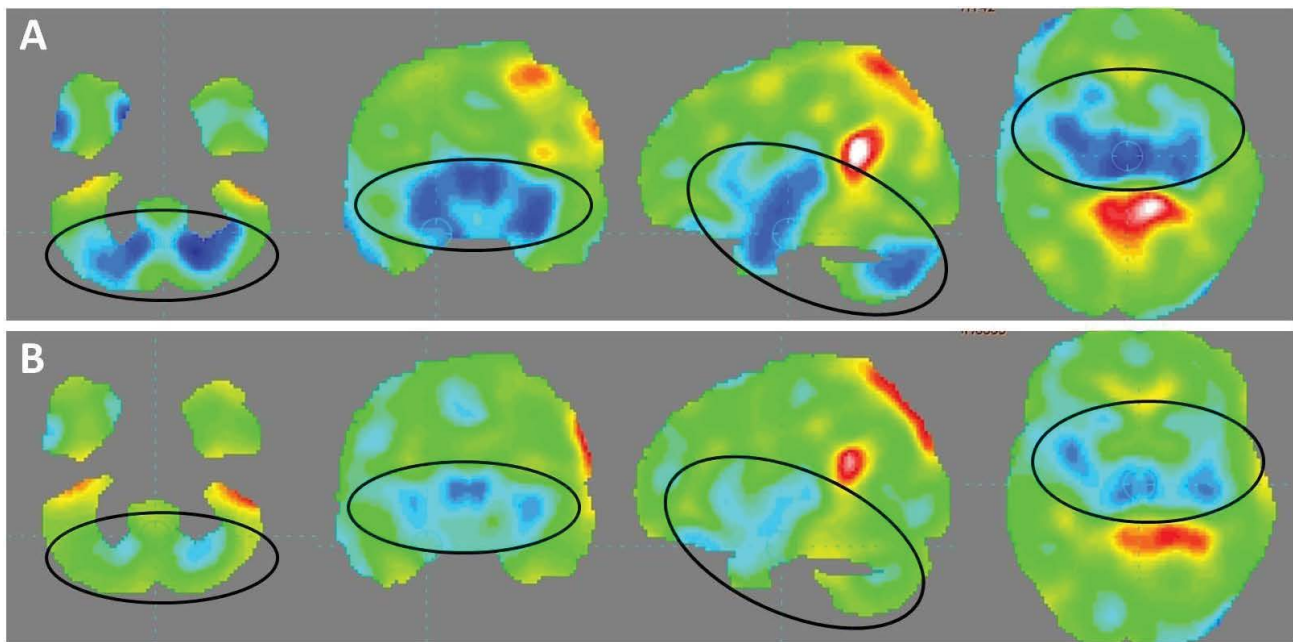
The conventional management of CP includes rehabilitation,

pharmacological intervention and surgical management, which are only targeted towards managing the symptoms [5]. Currently there is no cure for CP. The currently available therapies do not address the underlying pathology of neural tissue damage in CP. Hence, an alternative therapeutic strategy needs to be evolved.

Recently, cellular therapy has gained attention due to its ability of neuromodulation, neuroprotection, axon sprouting, neural circuit reconstruction, neurogenesis, neuroregeneration, neurorepair, and neuroreplacement [6]. To explore its benefits in CP, we administered autologous Bone Marrow Derived Mononuclear Cells (BMMNCs) intrathecally in a diagnosed patient of CP with Intellectual Disability.

## Case report

We present a case of eight years old boy diagnosed as cerebral palsy with intellectual disability. Patient was delivered by caesarean section and had delayed birth cry. He suffered from hypoxic brain injury followed by seizures at five hours of birth. He was admitted in the Neonatal Intensive Care Unit (NICU) for 10 days. Seizures continued till the age of 3–4 months and then had a repeat episode at eight years. At six years of age, he was diagnosed with cerebral palsy based on Magnetic Resonance Imaging (MRI) of brain. Since then he has been on neurorehabilitation along with medical treatment. His developmental milestones were delayed. Till the age of eight years, he had only achieved partial neck control. Current neurological evaluation demonstrated that, he had grade 1 spasticity in all four limbs with poor voluntary control. Head and trunk control was poor along with dissociation and equilibrium reactions. He had bilateral tendoachilles and hamstring tightness. Hand functions were not developed. Speech was monosyllabic. Eye contact was poor, there was lack of comprehension and social interaction was affected. His cognition and perceptual skills were not developed. However, he was able to recognize his mother. He was totally dependent on caregiver for all his daily activities and was nonambulatory. On Functional Independence Measure (WeeFIM), he scored 18/126. Gross Motor Function Classification System (GMFCS) – Expanded and Revised scale score was at level V and his gross motor function measure (GMFM) score was 1.9. MRI brain with 3D SPGR showed abnormality in bilateral thalami and perirolandic regions with thinning of the body of the corpus callosum, which represents sequelae of a perinatal hypoxic ischemic insult. Electroencephalogram (EEG) showed evidence of epileptiform activity over the bilateral and independent centro-temporal region. Positron Emission Tomography computed tomography (PET-CT) scan of the brain showed moderate hypometabolism in bilateral thalami and mild hypo metabolism in bilateral basal ganglia, bilateral mesial temporal lobes and bilateral cerebellar hemisphere (Figure 1A).



**Figure 1:** (A) Pre intervention PET-CT brain scan. Blue areas indicate hypometabolism before the intervention. (B) Post intervention PET-CT brain scan. PET-CT scan brain of the patient performed eight months after intervention wherein the blue areas have reduced significantly indicating improved metabolism of the brain.

The patient selection was in compliance with the World Medical Associations Helsinki declaration criteria. The protocol of autologous BMMNCs intrathecal administration was approved by the Institutional committee for Stem Cell Research and Therapy (IC-SCRT). The procedure was explained to patient's parents and an informed consent was obtained from them. Seventy two hours and 24 hours before transplantation, patient was administered with Granulocyte Colony-Stimulating Factor (G-CSF) to mobilize CD34+ cells. Eighty to Hundred ml of Bone marrow was aspirated from the iliac bone. MNCs were isolated from the bone marrow using density gradient separation method. The BMMNCs were checked for viability and evaluated for CD34+ by Fluorescence-activated cell sorting analysis. The cell sorting was done using CD34 PE antibody (BD Biosciences). Viability of the cells was found to be 99%.  $1.64 \times 10^8$  cells were transplanted immediately, in L4-L5 level. Three hundred mg Solumderol in 500 ml Isolyte P was simultaneously injected intravenously to improve stem cell multiplication to survival. After cellular transplantation, the patient was given customized neurorehabilitation which comprised of Neurodevelopmental Therapy (NDT) for the development of normal motor movements, strategies to improve equilibrium and positive supportive reaction, transition activities and exercises to improve weight bearing, exercises to develop trunk control and therapeutic activities to improve cognition and perceptual skills.

## Results

The patient was followed up at regular intervals and functional improvements were noted. One week after BMMNCs transplantation, he initiated lip rounding on stimulation along with tongue protrusion and palate touching. He also initiated chewing and sucking.

On follow up after eight months of intervention oromotor functions were seem to be improved. And he tried to chew biscuits. His visual tracking was improved and he could focus on the objects better than before. Hand functions improved he could now reach out for objects. He tried to do rolling activities.

His neck control and sitting balance also improved. Reduction in tendoachilles, hamstring tightness was also observed. Awareness and understanding of surroundings improved, so he was able to recognize family members. His GMFM score was increased from 1.9 to 3.077 whereas his GMFCS score remained same i.e. level V. WeeFIM scale score improved from 18/126 to 19/126. On comparing PET-CT scan brain performed before and eight months after the intervention, improvement was recorded in metabolic activity in amygdala, basal ganglia, cerebellar hemispheres, mesial temporal lobe, hippocampus, and thalami as indicated by change in the mean Standard Deviation (SD) (Table 1). Rest of the brain parenchyma revealed preserved 18F Fluorodeoxyglucose (FDG) uptake (Figure 1B).

## Discussion

Cerebral Palsy is a term describing a broad spectrum of non-progressive disorders affecting motor functions resulting from brain injury or malformations occurring before, during or after birth. Numerous preclinical studies have reported functional improvements in animal models of cerebral palsy after cellular therapy [7,8,9]. Safety of autologous BMMNCs has been demonstrated in various previously conducted studies [10]. Use of autologous cells is safe as it reduces the risk for immune rejection and is more effective as compared allogenic cells [11]. Intrathecal administration ensures targeted application of the injected cells into the central nervous system and also CSF possesses properties which support cell growth [12].

BMMNCs have unique ability of self-renewal and dedifferentiation which allows them to differentiate into different cell types from various germ layers [13]. They alter the micro- or macroenvironments of the damaged tissue. Via various paracrine mechanisms they carry out the repair process by axon regeneration, remyelination, immunomodulation, angiogenesis, stimulation of endogenous cells, etc [14]. Periventricular leukomalacia (PVL), a form of white matter injury, is a primary feature in cerebral palsy. PVL results in loss of oligodendrocytes which further

Brain areas		Pre Mean Std. Dev.	Post Mean Std. Dev	Correlating clinical functional improvements observed in patient
Amygdala	L	-4.5	-2.7	Memory, emotional reactions
	R	-5.6	-3.5	
Basal Ganglia	L	-2.7	-2.0	Voluntary control of motor movements, cognition, eye movements
	R	-4.2	-2.8	
Caudate Nucleus	L	-1.3	-1.6	Voluntary movement, learning, memory, and social behavior.
	R	-3.4	-2.3	
Cerebellum	L	-3.7	1.0	Motor control, coordination, attention,
	R	-3.2	1.5	
Hippocampus	L	-4.0	-0.2	Memory
	R	-3.9	-2.1	
Lenticular nucleus, pallidum	L	-2.0	-0.3	Movement control of limbs
	R	-3.3	-0.8	
Lenticular nucleus, putamen	L	-3.3	-2.0	Movement control of limbs
	R	-4.2	-3.2	
Lingual gyrus	L	3.6	1.0	Visual memory
	R	2.6	0.2	
Mesial temporal lobe	L	-2.5	-0.4	Long term memory
	R	-3.3	-1.5	
Posterior cingulate and paracingulate gyri	L	3.7	2.6	Learning, memory
	R	6.5	4.7	
Superior parietal gyrus	L	4.2	1.7	Spatial orientation
	R	5.3	4.2	
Thalamus	L	-6.1	-4.6	Sensory interpretation,
	R	-6.8	-5.1	

**Table 1:** Improvements in Mean Standard Deviation on PET-CT Scan of the brain

leads to damaged myelin and disrupted nerve conduction [15]. Evidence suggests that BMMNCs are able to differentiate into oligodendrocytes and astroglial cells which remyelinate the axons and improves neuronal connectivity [16].

The outcome of intervention was monitored using a repeat PET-CT scan brain along with objective scales like Gross Motor Function Measure (GMFM) and Wee FIM. The PET-CT scan was performed using the 18-F FDG radioisotope on a Siemens Biograph HD MDCT with LSO Detector technology. The Standardized Uptake Values (SUV) are standard quantitative measures of FDG uptake values which are used to monitor the outcome of intervention (Table 1). On Comparing the PET-CT scan brain before and after intervention, improved FDG uptake was recorded in hippocampus, basal ganglia and cerebellar hemisphere, partial improvement in amygdale and thalami. Previously hypometabolic (hypofunctioning) brain areas depicted as blue areas show improved metabolism post-intervention, represented by green areas. The images reveal a balancing effect on overall brain metabolism (Figure 1). The changes in brain metabolism correlated with functional improvements observed in patient as mentioned in result. (Table 1) These functional improvements were further supported by improved GMFM score from 1.9 to 3.077% which revealed the improvement in his functional movements.

There are some limitations of this case study as we have no control, however the patient can be considered as self-control because the improvements were seen after the combination of stem cell therapy and neurorehabilitation and not with rehabilitation alone. Serum biomarkers were not used to measure the release of various factors by transplanted cells, but PET-CT scan was used as biomarker which demonstrated significant improvements.

Intrathecal Autologous BMMNCs transplantation may be a safe treatment strategy and holds significant therapeutic potential in combination with standard treatment for cerebral palsy. As

observed in this case, neurorehabilitation augments the positive effect of cellular therapy. PET-CT scan can be effectively used to monitor changes occurring at cellular level after the intervention.

## References

- Rosenbaum P, Paneth N, Leviton A, Goldstein M, Bax M, Damiano D et al. A report: the definition and classification of cerebral palsy. *Dev Med Child Neurol Suppl.* 2007;109:8-14.
- Rosen MG, Dickinson JC. The incidence of cerebral palsy. *Am J Obstet Gynecol.* 1992;167(2):417-23.
- Reddihough DS, Collins KJ. The epidemiology and causes of cerebral palsy. *Aust J Physiother.* 2003;49(1):7-12.
- Paneth N, Hong T, Korzeniewski S. The descriptive epidemiology of cerebral palsy. *Clin Perinatol.* 2006;33(2):251-67.
- Quality Standards Subcommittee of the American Academy of Neurology and the Practice Committee of the Child Neurology Society, Delgado MR, Hirtz D, Aisen M, Ashwal S, Fehlings DL, McLaughlin J, et al. Practice parameter: pharmacologic treatment of spasticity in children and adolescents with cerebral palsy (an evidence-based review): report of the Quality Standards Subcommittee of the American Academy of Neurology and the Practice Committee of the Child Neurology Society. *Neurology.* 2010 26;74(4):336-43. doi: 10.1212/WNL.0b013e3181cbcd2f.
- Woodbury D, Schwarz EJ, Prockop DJ, Black IB. Adult rat and human bone marrow stromal cells differentiate into neurons. *J Neurosci Res.* 2000;61(4):364-70.
- Chen J, Yang Y, Shen L, Ding W, Chen X, Wu E, et al. Hypoxic Preconditioning Augments the Therapeutic Efficacy of Bone Marrow Stromal Cells in a Rat Ischemic Stroke Model. *Cell Mol Neurobiol.* 2016.
- Huang HZ, Wen XH, Liu H, Huang JH, Liu SQ, Ren WH, et al. [Human umbilical cord blood mononuclear cell transplantation promotes long-term neurobehavioral functional development of newborn SD rats with hypoxic ischemic brain injury]. *Zhonghua Er Ke Za Zhi.* 2013;51(6):460-6. [Article in Chinese].

9. Rosenkranz K, Kumbruch S, Tenbusch M, Marcus K, Marschner K, Dermietzel R, et al. Transplantation of human umbilical cord blood cells mediated beneficial effects on apoptosis, angiogenesis and neuronal survival after hypoxic-ischemic brain injury in rats. *Cell Tissue Res.* 2012;348(3):429-38. doi: 10.1007/s00441-012-1401-0.
10. Alok Sharma, Nandini Gokulchandran, Hemangi Sane, Avantika Patil, Akshata Shetty, Hema Biju, et al. Amelioration of Autism by Autologous Bone Marrow Mononuclear Cells and Neurorehabilitation: A Case Report. *American Journal of Medical Case Reports* 2015;3:304-09. doi: 10.12691/ajmcr-3-10-1.
11. Jung DI, Ha J, Kang BT, Kim JW, Quan FS, Lee JH, et al. A comparison of autologous and allogenic bone marrow-derived mesenchymal stem cell transplantation in canine spinal cord injury. *J Neurol Sci.* 2009;285(1-2):67-77. doi: 10.1016/j.jns.2009.05.027.
12. Miyan JA, Zendah M, Mashayekhi F, Owen-Lynch PJ. Cerebrospinal fluid supports viability and proliferation of cortical cells in vitro, mirroring in vivo development. *Cerebrospinal Fluid Res.* 2006;3:2.
13. Burlacu A, Grigorescu G, Rosca AM, Preda MB, Simionescu M. Factors secreted by mesenchymal stem cells and endothelial progenitor cells have complementary effects on angiogenesis in vitro. *Stem Cells Dev.* 2013;22(4):643-53. doi: 10.1089/scd.2012.0273.
14. Xiang MX, He AN, Wang JA, Gui C. Protective paracrine effect of mesenchymal stem cells on cardiomyocytes. *J Zhejiang Univ Sci B.* 2009;10(8):619-24. doi: 10.1631/jzus.B0920153.
15. Silbereis JC, Huang EJ, Back SA, Rowitch DH. Towards improved animal models of neonatal white matter injury associated with cerebral palsy. *Dis Model Mech.* 2010;3(11-12):678-88. doi: 10.1242/dmm.002915.
16. Akiyama Y, Radtke C, Honmou O, Kocsis JD. Remyelination of the spinal cord following intravenous delivery of bone marrow cells. *Glia.* 2002;39(3):229-36.

**\*Corresponding Author:** Pooja Kulkarni, NeuroGen Brain and Spine Institute, StemAsia Hospital & Research Centre, Sector 40, Plot No 19, Palm Beach Road, Seawoods (W), New Mumbai, Maharashtra, India, 400706, E-mail: [publications@neurogen.in](mailto:publications@neurogen.in)

**Received Date:** November 17, 2016, **Accepted Date:** February 13, 2017, **Published Date:** February 23, 2017.

**Copyright:** © 2017 Sharma A, et al. This is an open access article distributed under the Creative Commons Attribution License, which permits unrestricted use, distribution, and reproduction in any medium, provided the original work is properly cited.

**Citation:** Sharma A, Sane H, Kalburgi S, Kulkarni P, Bhagwanani K, et al. (2017) Autologous Bone Marrow Mononuclear Cell Transplantation with Neurorehabilitation for Cerebral Palsy. *J Stem Trans Bio* 2(1): 110.