

## Effect of Cellular Therapy seen on Musculoskeletal Magnetic Resonance Imaging in a Case of Becker's Muscular Dystrophy



Alok Sharma<sup>1</sup>, Hemangi Sane<sup>2</sup>, Amruta Paranjape<sup>2</sup>, Purna Badhe<sup>1</sup>, Nandini Gokulchandran<sup>1</sup>, Verghese Jacob<sup>3</sup>

From the Department of Medical Services and Clinical Research<sup>1</sup>, Department of Research and Development<sup>2</sup>, Department of Neuro-rehabilitation<sup>3</sup>; NeuroGen Brain and Spine Institute, Chembur, Mumbai-400071, Maharashtra, India.

### Abstract:

Becker's Muscular dystrophy (BMD) is a disorder with a progressive course of muscle weakness leading to disability and premature death. Pharmacological and rehabilitative management is supportive and does not halt the progression of the disease. Novel treatment options of gene therapy and stem cell therapy may provide a promising solution by altering the basic pathology of the disease. Pre-clinical studies have shown safety and beneficial effects of bone marrow derived mononuclear cells transplantation in BMD.

In this case report, we treated a patient of BMD with a new multidisciplinary approach of Autologous Bone Marrow Mono Nuclear Cells (BMMNCs) followed by rigorous rehabilitation. The BMMNCs were transplanted via the intrathecal and intramuscular routes. The effects were measured in terms of clinical, functional and radiological changes. At 6 months after therapy the comparative Musculoskeletal Magnetic Resonance Imaging (MRI-MSK) showed regeneration of muscle fibers. This observation is one of the initial evidential data for muscle regeneration, in BMD patient, following cellular therapy. Although an observation only in a single case, it may support undertaking further research. Large clinical trials are required, with more robust methodology. MRI-MSK may also be evaluated for monitoring the effects of cellular therapy.

**Key words:** Cellular Therapy, Becker's Muscular Dystrophy, Magnetic Resonance Imaging, Muscle regeneration, Autologous, Bone marrow, Mononuclear cells, Adult stem cells, Stem cell therapy.

### Introduction

Becker's Muscular dystrophy (BMD) is a genetically inherited disorder manifested as progressive muscle degeneration. Common symptoms are progressive muscle weakness, pseudo-hypertrophy and atrophy which leads to contractures, scoliosis, structural and postural deformities, and functional dependency

[1]. Cardiomyopathy and respiratory muscle weakness leads to premature death [2]. North KN *et al* have also observed reduction in Intelligence Quotient (IQ) in subclinical cases of BMD [3]. The diagnosis of BMD is based on clinical findings, increased serum creatine phosphokinase (CPK)

**Corresponding Author:** Amruta Paranjape

Email: [publications@neurogen.in](mailto:publications@neurogen.in)

**Received:** 18-10-2013 | **Accepted:** 23-11-2013 | **Published Online:** 5-11-2013

This is an Open Access article distributed under the terms of the Creative Commons Attribution License ([creativecommons.org/licenses/by/3.0](http://creativecommons.org/licenses/by/3.0))

**Conflict of interest:** None declared | **Source of funding:** Nil

levels, Electromyography and nerve conduction velocity (EMG-NCV) study, Musculoskeletal Imaging (MRI-MSK), genetic analysis and muscle biopsy [1,2,4]. MRI is considered to be the most suitable modality for soft tissue imaging due to its inherent high soft tissue resolution and discrimination between fat, muscles, fluids, edema and bones [5]. MRI – MSK has been used to confirm the dystrophic changes in the muscles [6]. The current management of BMD is multidisciplinary, which consist of medical management and rehabilitation. It aims to maintain the functional level and delay dependence but does not alter the course of the disease or pathology [1,7]. The pharmacological management includes use of steroids, proteases and anti-oxidants [7] to reduce the early inflammatory changes and delay the process of muscle degeneration; however, it is still inevitable. None of these treatment options provide a promising reversal of the disease process. Preclinical evidence for cellular therapy shows muscle regeneration, dystrophin expression and altered course of the disease. Autologous BMMNCs transplantation has earlier been shown to be safe in humans with various neuromuscular diseases [8-10]. We present a case of a 28 year old male suffering from BMD treated with adult autologous bone marrow derived mononuclear cell transplantation.

### Case Report

We treated a 28 year old male patient of BMD with cellular therapy. His parents had consanguineous marriage. He had no family history of similar disease. At the age of 8 years he developed weakness in both the lower limbs which progressed to other regions of the body. This led to functional restrictions in stair climbing and walking. He started walking on toes at the age of 12 and the weakness progressed to upper limbs causing inability to perform overhead activities. He was wheel chair bound by the age of 20. Diagnosis of BMD was confirmed based on clinical features, EMG, serum

CPK levels and genetic analysis. He had not received any rehabilitative therapies at home.

On assessment before cellular transplantation, he had bilateral foot drop, forearm supination contracture, tongue hypertrophy. Neurological examination revealed hypotonia and hyporeflexia. He had no sensory or cognitive impairment. Muscle strength was measured using manual muscle testing (MMT) and dynamometer testing for grip and pinch strength. MMT of the proximal muscles of the hip and shoulder scored 2 whereas distal muscles of knee, ankle, elbow and wrist scored 3. Neck musculature scored 2 and trunk scored 1. Only the distal group of muscles showed the strength above functional level. Hand dynamometer measured 15 pounds on the right side and 16.67 pounds on the left side. Pinch grip measured 1.34 pounds on the right side and 2.34 pounds on the left side. Patient could not maintain quadruped position for more than 1 minute due to diffuse upper extremity pain. He could stand only for 3 minutes in a standing frame due to calf pain. He was moderately dependent on others for his activities of daily living (ADL) with the Functional Independence Measure (FIM) score of 55.

Serum CPK (663 U/L) and Creatine Kinase – MB (CK-MB) (23 U/L) levels were elevated. EMG-NCV study showed low amplitude Motor Compound Muscle Action Potential (CMAP) and low amplitude F – reflexes for bilateral median, ulnar, tibial, peroneal, axillary, radial, musculocutaneous, common peroneal, femoral and tibial nerves. These findings confirmed the presence of primary muscular disease. MRI showed extensive hyper intense areas of fatty infiltration in pelvic girdle, bilateral thigh muscles, legs, arms and forearm muscles. Neurovascular bundles were well maintained. These findings were consistent with the dystrophic changes in the muscles. Left Ventricular Ejection Fraction (LVEF) was found to be 35% on 2D echo. Genetic analysis showed deletion of exons 10, 11, 12, 13, 17, 19, 20, 21 in dystrophin gene.

## Material and Methods

A duly filled informed consent was obtained. Selection of this patient for the treatment was based on World Medical Associations Revised Declaration of Helsinki [11]. The ethical approval was obtained from Institutional committee for Stem Cell Research and Therapy (IC-SCRT), NeuroGen, Brain and Spine Institute, Mumbai, India.

Patient underwent serological, biochemical and hematological blood tests, chest X-ray a week before adult autologous BMMNC transplantation to ensure preoperative fitness. MRI –MSK, EMG – NCV study was also done a week prior to validate the effects of the treatment. The MRI – MSK was taken using a 1.5 Tesla, HD 8 channel MRI unit (Signa, GE Medical Systems, Milwaukee, Wisconsin). Protocol included T1 – weighted coronal and axial images. MRI parameters were TR ( Time to repetition ) 720 milliseconds , TE ( Time to Echo ) 12.7 milliseconds , FOV ( Field of View) 48 x 48, 4 mm slice thickness and 5 mm spacing. Granulocyte colony stimulating factor (GCSF) was administered subcutaneously 48 hours and 24 hrs prior to the MNCs transplantation to stimulate CD34+ cells and enhance their survival and multiplication [12]. On admission, detailed assessment was carried out by a range of medical and allied health professionals. Motor points, the point where the innervating nerve enters the muscle belly, were identified with the help of electrical muscular stimulation and marked by an experienced physiotherapist. The muscles with the strength below functional level that were most pertinent to regain functional independence were selected. On the day of transplantation 120 ml bone marrow was aspirated from anterior superior iliac spine under local anesthesia, using bone marrow aspiration needle and was collected in heparinized tubes. Density gradient method was used to separate the mononuclear cells (MNCs) from the aspirate. Fluorescence activated cell sorting (FACS) analysis showed 94% viability of the cells and CD34+

count to be 1.36%. The separated cells were then diluted in cerebrospinal fluid (CSF) and injected intrathecally at the level between L4 and L5 and intramuscularly in the specific motor points of the deltoid, biceps, brachioradialis, extensor digitorum, glutei, quadriceps, hamstrings, tibialis anterior, peronei, abdominals, back extensors and trapezius bilaterally. Simultaneous intravenous administration of 1 gm methyl prednisolone in 500 ml of Ringer Lactate solution was carried out. Total number of cells injected via both the routes was 67x10<sup>6</sup>.

This was followed by multidisciplinary rehabilitation. Physiotherapy consisted of bed mobility exercises, training for various transfers and suspension exercises. He was trained for standing with a standing frame. Exercises aimed at strengthening the muscles were performed at moderate intensity. Occupation therapy consisted of strengthening exercises of bilateral upper limb and trunk muscles and training for ADL. Psychological counseling was used for anger management and cognitive therapy for reducing the feeling of helplessness and hopelessness.

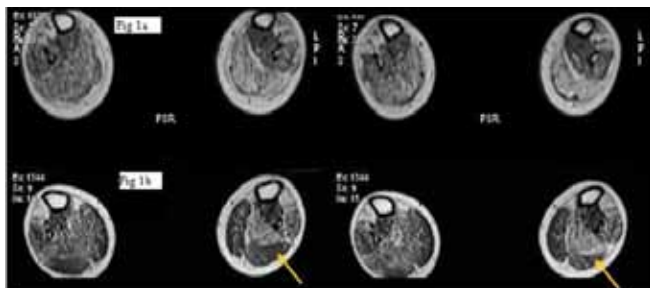
The patient was discharged at one week and was advised to continue the rehabilitation at home. The follow up assessment was conducted after three and six months. At six months after the first transplantation the MRI – MSK scan and EMG – NCV study was repeated. MRI – MSK was conducted on the same MRI unit with same parameters as earlier. Nine months later, second dose was administered to maintain the improvement achieved after the first transplantation. He was subsequently monitored for one year.

## Results

Patient had no minor or major adverse effects following the BMMNCs transplantation. At one

week, duration of standing increased from 3 minutes to 20 minutes. He was able to walk for 5 minutes with the help of calipers and varying degree of human support. Exercise tolerance had improved. At 3 months following first BMMNCs transplantation, manual muscle strength testing showed improvement in all muscles groups and patient reported decreased generalized fatigue. Further improvement in exercise tolerance was also noted.

At 6 months after the first BMMNCs transplantation, patient could walk using push knee splint and support of one person. He reported reduction in the calf pain while standing and reduced diffused upper extremity pain in the upper limbs while maintaining the all four's position. A repeat MRI – MSK showed increased isointense areas suggesting minimal increase in the muscle fibers and reduction in fatty infiltration in bilateral peroneus longus and brevis [Fig.1 a, 1 b], bilateral lateral heads of gastrocnemius and soleus [Fig.2a,2b], bilateral long, medial and lateral heads of triceps [Fig.3a,3b]. EMG – NCV study findings did not show any change.



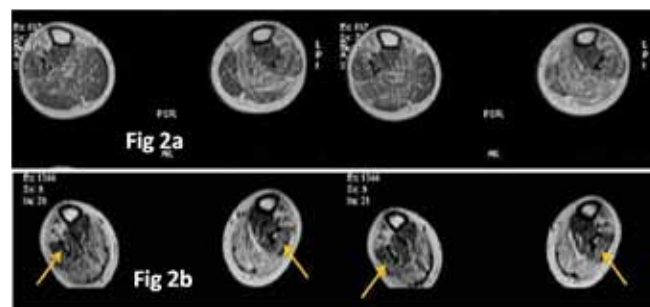
**Fig.1a:** T1 Weighted axial MRI Images of Peroneus Longus and Brevis, before BMMNCs transplantation  
**Fig.1b:** T1 Weighted axial MRI Images of Peroneus Longus and Brevis, 6 months after BMMNCs transplantation showing increased isointense areas suggesting muscle regeneration and reduced fatty infiltration as pointed by the arrows.

At 9 months after the first BMMNCs transplantation, the MMT score grading did not change but the control and quality of movement had improved, grip strength increased to 27.5 pounds on the right side (from 15 pounds pretreatment) and 25 pounds on left (from 16.67 pounds pretreatment) and pinch strength showed minimal changes on both sides. Patient could maintain the quadruped position for 10 min and the upper extremity pain had reduced. Patient could walk up to an hour without fatigue with the splint and support from one person. Pain in the calf had reduced while walking. He could perform the exercise with much more ease and exercise tolerance and endurance had significantly improved. The functional status was maintained on FIM scale with the score of 55.

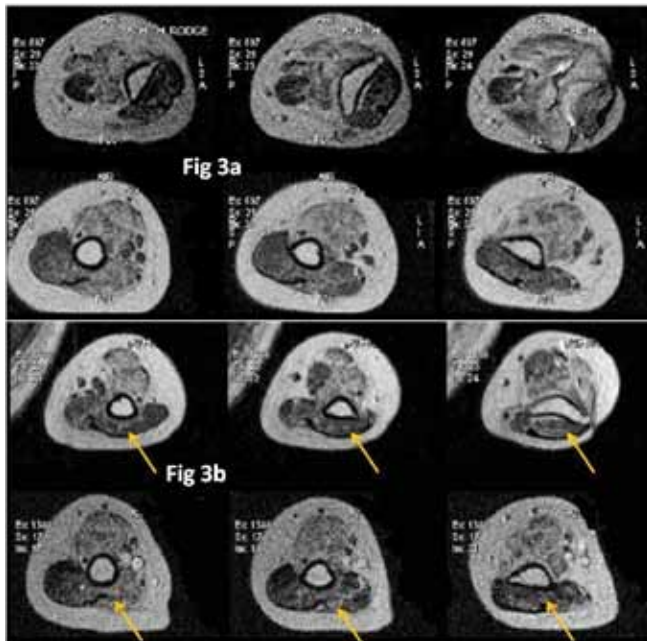
There were no side effects noted and the improvements were maintained till the end of 21 months.

### Discussion

Various genes and gene loci have been identified to undergo mutation, deletion or duplication resulting



**Fig.2a:** T1 Weighted axial MRI Images of Gastrocnemius and Soleus, before BMMNCs.  
**Fig.2b:** T1 Weighted axial MRI Images Gastrocnemius and Soleus, 6 months after BMMNCs transplantation showing increased isointense areas suggesting muscle regeneration and reduced fatty infiltration as indicated by the arrows.



**Fig.3a:** T1 Weighted axial MRI Images of Left and Right Long, Medial and Lateral head of Triceps, before BMMNCs transplantation.

**Fig.3b:** T1 Weighted axial MRI Images of Left and Right Long, Medial and Lateral head of Triceps, 6 months after BMMNCs transplantation showing increased isointense areas suggesting muscle regeneration and reduced fatty infiltration as pointed by the arrows.

in Muscular dystrophy (MD) [1-3]. These mutations result in reduced proportion of fast twitch muscle fibers and increased proportion of slow twitched fibers. The muscle cell membranes and cytoskeletons become more fragile which can be easily disrupted by mechanical forces. The calcium deregulation in the muscle cells results in contractile deficiencies. The common features of MD are atypical muscle fiber size, muscle necrosis and increased amount of fat and connective tissue in the muscles [1,13]. The intrinsic repair of skeletal muscle relies on the resident reserve pool of undifferentiated mononuclear cells, termed “satellite cells” which are in a quiescent stage. They are activated in response to injury, to mediate muscle regeneration.

Satellite cell progeny, termed myoblasts, divide and differentiate to get incorporated into muscle fibers. Initially, the new muscle fibers are formed by satellite cells. But as the satellite cell pool is depleted, the muscle degeneration is progressive, irreversible and muscle fibers are replaced by fibrotic tissue [14]. Recently with advances in molecular biology new treatment options in the form of gene therapy and stem cell therapy are being explored [15]. Gene therapy consists of introducing the missing gene through plasmids aiming to correct the point mutations. However, it hasn't been clinically tested as yet and this may elicit an immune response. Additionally, the dystrophin gene which is absent or defective in most of the muscular dystrophies is too big to be carried by the vector. Subsequently, gene therapy aimed at actual cell transfer of genetically modified myoblasts in the myopathic muscular bed [16]. Further studies, explored the ability to transfer the progenitor cells with the myogenic potential from various sources. The transfer of such primitive cellular forms is the basis of stem cell therapy and is postulated to have increased capability to regenerate the muscle fibers than myoblasts [17]. A variety of cells derived from different tissues have been previously used to study their effect on the dystrophin gene expression in animals and human beings [16,18]. Numerous studies show beneficial effects of bone marrow derived cellular transfer in muscular dystrophy. The cellular transfer initiate angiogenesis, activate satellite cells to injury site hastening the repair process, stimulates release of various growth factors, reduces inflammatory response, and enhances control over cell apoptotic processes and immune-response [19-21]. These effects are termed as paracrine effects and one may debate that it is, these paracrine mechanisms, what bring about the desired effects of the cellular therapy. Taking into consideration the evidence behind the use of bone marrow derived stem cells we treated our patient with Autologous Bone Marrow Derived Mono Nuclear Cells.

Delivery of stem cells at the desired location poses practical difficulties in MDs, as the cells need to be delivered to all the muscles in the body. Intravenous application of bone marrow derived stem cells in animal models has shown successful homing of the stem cells to injured muscular tissues, however this also risks dilution of the cell concentration. Although muscular dystrophy is mainly perceived primarily as the disease of the muscles, some early evidence suggests neuromuscular involvement. Dystrophin is a part of the structural protein in nerves and found in the myelin forming schwann cells [22]. Abnormalities in these cells can lead to demyelination and degeneration like changes in the nerves. We therefore chose two different modes of cell transplantation, intramuscular and intrathecal. Injecting the bone marrow MNCs at motor points of weak muscles targeted the repair of the innervating nerve as well as the muscles. CSF was used as diluting medium, since it is known to harbor growth factors which help the growth of the cortical epithelium and promote vascularization in the nervous system [23]. Endurance and physical training protocols in patients suffering from BMD have shown beneficial effects in some cases [24], BMMNC transplantation was therefore followed by rigorous rehabilitation.

Along with clinical and functional assessment, we used MRI-MSK as an outcome measure to assess the changes in the muscle after cellular therapy. Advanced non-invasive radio-imaging techniques have been found to be accurate in diagnosing and monitoring MD [25]. MRI has several advantages over other imaging techniques used in BMD. Distinct from ultrasound scan it is operator independent and unlike Computer Tomography (CT) scan it does not use ionizing radiations. There is no need to administer an intravenous contrast for image acquisition. Multiplanar acquisition in MRI makes it easier to be used for the patients with contractures, deformities and severe muscle weakness as seen in BMD. MRI also has an inherently high soft

tissue resolution and discrimination potential for fat, muscles, fluids, edema and bones. BMD is a disease characterized by muscle atrophy and fatty replacement [4]. MRI therefore appeals as the most pertinent imaging modality to monitor disease progression. MRI has earlier been used in Duchenne muscular dystrophy (DMD), which is pathologically a more severe form of BMD, to identify patterns of muscle weakness, disease progression and therapeutic effect of various treatments [5]. There is scarce evidence for the use of MRI to assess disease progression and monitor the treatment effect in BMD. Tasca *et al*, assessed 46 patients suffering from BMD to understand the patterns of muscle involvement. This was however a cross-sectional observation [6]. In our study we studied the therapeutic effect of cellular therapy on BMD using an MRI over a period of 8 months. There was an increase in the muscle fibers of peronei, gastrosoleus and long, medial and lateral head of triceps with decreased fatty infiltration as observed on the MRI-MSK post 6 months of cellular transplantation. Clinically there was improved standing balance, ability to walk with the help of push knee splint and unilateral human support. There was reduction in calf pain while standing and upper extremity pain while maintaining the quadruped position. All these activities involve the above mentioned muscles. An important point to be noted is absence of any side effects. The improved quality of movement may suggest better recruitment of the existing muscle fibers.

## Conclusion

This case report suggests that cumulative effects of cellular transplantation and rehabilitation may have the potential to repair and regenerate the muscle fibers in MD. It also substantiates the claims that BMMNCs transplantation can regenerate muscle fibers in patients suffering from BMD and MRI-MSK may serve as imaging modality to monitor the effects. It is one of the first evidential data for

muscle regeneration, in BMD patient, following cellular therapy. Although this is an observation in a single patient, it may support undertaking further research. Large clinical trials are required, with more robust methodology to assess the effectiveness of BMMNCs transplantation to regenerate muscle fibers in case of BMD and evaluate the use of MRI-MSK for monitoring the disease progression.

## References:

1. Sharma A, Badhe P, Gokulchandran N, Chopra G, Lohia M, Kulkarni P. Stem cell therapy and other recent advances in Muscular dystrophy. Neurogen Brain and Spine Institute (EDs) publication; Mumbai. 2011.
2. Verhaert D, Richards K, Rafael-Fortney J, Raman S. Cardiac involvement in patients with muscular dystrophies: magnetic resonance imaging phenotype and genotypic considerations. *Circ Cardiovasc Imaging*. 2011;4(1):67-76.
3. North K, Miller G, Iannaccone S, Clemens P, Chad D, Bella I, *et al*. Cognitive dysfunction as the major presenting feature of Becker's muscular dystrophy. *Neurol*. 1996;46(2):461-465.
4. Orrell RW. Diagnosing and managing muscular dystrophy. *Practitioner*. 2012;256(1754):21-24.
5. Noseworthy M, Davis A, Elzibak A. Advanced MR imaging techniques for skeletal muscle evaluation. *Semin Musculoskelet Radiol*. 2010;14(2):257-268.
6. Tasca G, Iannaccone E, Monforte M, Masciullo M, Bianco F, Laschena F, *et al*. Muscle MRI in Becker muscular dystrophy. *Neuromuscul Disord*. 2012;22 Suppl 2:S100-106.
7. Chakkalakal J, Thompson J, Parks R, Jasmin B. Molecular, cellular, and pharmacological therapies for Duchenne/Becker muscular dystrophies. *FASEB J*. 2005;19(8):880-891.
8. Purandare C, Shitole DG, Belle V, Kedari A, Bora N, Joshi M. Therapeutic potential of autologous stem cell transplantation for cerebral palsy. *Case Rep Transplant*. 2012;2012:825289
9. Prabhakar S, Marwaha N, Lal V, Sharma RR, Rajan R, Khandelwal N. Autologous bone marrow-derived stem cells in amyotrophic lateral sclerosis: a pilot study. *Neurol India*. 2012;60(5):465-469.
10. Sharma A, Gokulchandran N, Chopra G, Kulkarni P, Lohia M, Badhe P, *et al*. Administration of autologous bone marrow-derived mononuclear cells in children with incurable neurological disorders and injury is safe and improves their quality of life. *Cell Transplant*. 2012; 21 Suppl 1:S79-90.
11. Carlson R, Boyd K, Webb D. The Revision of The Declaration of Helsinki: Past, Present And Future. *Br J Clin Pharmacol*. 2004;57:695-713.
12. Petit I, Szyper-Kravitz M, Nagler A, Lahav M, Peled A, Habler L, *et al*. G-CSF induces stem cell mobilization by decreasing bone marrow SDF-1 and up-regulating CXCR4. *Nature Immunolog*. 2002;3:687-694.
13. Fink R, Stephenson D, Williams D. Physiological properties of skinned fibers from normal and dystrophic (Duchenne) human muscle activated by  $Ca^{2+}$  and  $Sr^{2+}$ . *J Physiol*. 1990;420:337-353.
14. Collins CA, Partridge TA. Self-renewal of the adult skeletal muscle satellite cell. *Cell Cycle*. 2005; 4(10):1338-1341.
15. Karpati G, Gilbert R, Petrof BJ, Nalbantoglu J. Gene therapy research for Duchenne and Becker muscular dystrophies. *Curr Opin Neurol*. 1997;10(5):430-435.
16. Tremblay J, Skuk D, Palmieri B, Rothstein D. A case for immunosuppression for myoblast transplantation in Duchenne muscular dystrophy. *Mol Ther*. 2009;17(7):1122-1124.
17. Cossu G, Mavilio F. Myogenic stem cells for the therapy of primary myopathies: wishful thinking or therapeutic perspective? *J Clin Invest*. 2000; 105(12):1669-1674.
18. Sirabella D, De Angelis L, Berghella L. Sources for skeletal muscle repair: from satellite cells to

- reprogramming. *J Cachexia Sarcopenia Muscle*. 2013;4(2):125-136
19. Chen P, Yen M, Liu K, Sytwu H, Yen B. Immunomodulatory properties of human adult and fetal multipotent mesenchymal stem cells. *J Biomed Sci*. 2011;18:49.
  20. Crisostomo P, Wang M, Herring C, Markel T, Meldrum K, Lillemoe K. Gender differences in injury induced mesenchymal stem cell apoptosis and VEGF, TNF, IL-6 expression: Role of the 55 kDa TNF receptor (TNFR1). *J Mol Cell Cardiol*. 2007;42(1):142-149.
  21. Burlacu A, Grigorescu G, Rosca A, Preda M, Simionescu M. Factors secreted by mesenchymal stem cells and endothelial progenitor cells have complementary effects on angiogenesis in vitro. *Stem Cells Dev*. 2012; 15;22(4):643-653.
  22. Nguyen T, Ellis J, Love D, Davies K, Gatter K, Dickson G, Morris G. Localization of the DMDL gene-encoded dystrophin-related protein using a panel of nineteen monoclonal antibodies: presence at neuromuscular junctions, in the sarcolemma of dystrophic skeletal muscle, in vascular and other smooth muscles, and in proliferating brain cell lines. *J Cell Biol*. 1991; 115(6):1695-1700.
  23. Miyani J, Zendah M, Mashayekhi F, Owen-Lynch P. Cerebrospinal fluid supports viability and proliferation of cortical cells in vitro, mirroring in vivo development. *Cerebrosp Flu Res*. 2006; 3:2.
  24. Roque J, Carvalho V, Pascoalino L, Ferreira S, Bocchi E, Guimarães G. Physical training in Becker muscular dystrophy associated with heart failure. *Arq Bras Cardiol*. 2011;97(6):e128-31.
  25. Kinali M, Arechavala-Gomez V, Cirak S, Glover A, Guglieri M, Feng L, *et al*. Muscle histology vs. MRI in Duchenne muscular dystrophy. *Neurol*. 2011;76(4):346-353.